

Use of bisphosphonates in the treatment of pediatric osteoporosis

Bisphosphonates are increasingly prescribed for children with primary and secondary osteoporosis. Despite this, many questions remain as to the optimal agent, and the dose and duration of therapy, particularly considering the unique issues related to the growing skeleton. While much is now understood regarding their use in one of the most debilitating forms of childhood osteoporosis (osteogenesis imperfecta), their role in the treatment of secondary osteoporosis is less clearly defined. The purpose of this review is to highlight the impact of bisphosphonate use on the growing skeleton and to review the current evidence for bisphosphonate administration in primary and secondary childhood osteoporosis. In particular, we discuss the evidence for clinical benefit (including functional outcomes beyond bone mineral density) and review the issues related to known and theoretical side effects. Finally, we provide specific recommendations for the use of bisphosphonates in pediatric osteoporosis, including guidelines for monitoring treatment outcomes. This review has been developed for educational purposes by the Drugs and Therapeutics Committee of the Lawson Wilkins Pediatric Endocrine Society.

KEYWORDS: bisphosphonates ■ children ■ osteoporosis ■ pediatrics ■ treatment

The use of bisphosphonates (BPs) in children has increased over the past few decades, particularly since the description of their beneficial effect among children with one of the most debilitating forms of osteoporosis – moderate and severe osteogenesis imperfecta (OI). In this review, we discuss the mechanism of action of these agents on bone, with particular attention to their unique effects on the growing skeleton. We also summarize the evidence for their use in the most common of the reported clinical contexts: low bone mass and bone fragility (osteoporosis). Finally, we analyze the known risks and benefits of BPs for children with established osteoporosis or risk factors for compromised bone health, and provide recommendations for their administration to children. This review was developed by the Drugs and Therapeutics Committee of the Lawson Wilkins Pediatric Endocrine Society to be of educational value for practitioners. It does not indicate an official policy or guideline of the Society.

Structure of BPs & mechanism of action on bone

The mechanism of action and the pharmacology of BPs have been detailed in a recent review by Russell [1]. In brief, BPs are chemical analogs of pyrophosphate, in which the oxygen atom is replaced by a carbon atom (P-C-P instead of P-O-P) [2]. This substitution confers resistance

to hydrolysis in the gastrointestinal tract and to enzymatic cleavage by alkaline phosphatase. By adhering to the bone surface, BPs come into close contact with osteoclasts. The low pH of the osteoclast microenvironment results in the breakdown of hydroxyapatite, release of BPs and their subsequent internalization by osteoclasts where they accumulate in high concentrations, despite less than 1–5% absorption from the gastrointestinal tract [1,3–5]. The R1 side chain of BPs is usually a hydroxyl group (except for chlorine in clodronate), which, along with the phosphate groups, acts as a ‘bone hook’, increasing the affinity for calcium [1,5]. The R2 side chain modifications determine the antiresorptive potency of BPs. In the first generation BPs, such as etidronate and clodronate, R2 is a simple alkyl or halogen group, respectively. Introduction of the nitrogen atom at R2 (pamidronate, alendronate, ibandronate, neridronate and olpadronate), particularly within a heteroaromatic ring (zoledronate and risedronate), increases *in vitro* antiresorptive potency [6–9]. The half-life and the recommended treatment doses and duration of treatment vary between various classes of BPs. The treatment protocols for pediatric disorders have been recently reviewed by Bachrach and Ward [10].

The mechanisms of BP action on osteoclasts can be conceptually grouped into two categories: physicochemical and cellular, the end result

Leanne M Ward^{1,2†},
Anna Petryk³ &
Catherine M Gordon⁴

[†]Author for correspondence:

¹Room 250H, Research
Institute, Children’s Hospital of
Eastern Ontario, 401 Smyth Rd,
Ottawa, Ontario K1H 8L1,
Canada

Tel.: +1 613 737 2253

Fax: +1 613 738 4236

lward@cheo.on.ca

²University of Ottawa, Ottawa,
Ontario, Canada

³University of Minnesota
Amplatz Children’s Hospital,
MN, USA

⁴Children’s Hospital Boston,
Harvard Medical School,
MA, USA

being apoptosis and/or impairment of cellular functions of osteoclasts (FIGURE 1) [1]. The first is based on a direct cytotoxic effect of high levels of BPs within the osteoclast and is typical of first-generation non-nitrogen-containing BPs (non-N-BPs). The second involves interaction with the mevalonate pathway, mainly by inhibiting farnesyl diphosphate (FPP) synthase [11,12], which is the main mode of action of nitrogen-containing BPs (N-BPs) [13–16]. Inhibition of FPP leads to

reduced prenylation, a post-translational modification involving transfer of isoprenoid lipids. By increasing hydrophobicity, this process promotes the attachment of proteins to cell membranes, as well as protein–protein interactions [17]. Proteins that undergo prenylation include GTP-binding proteins (Ras, Rac, Rab and Rho), which regulate osteoclast function, including cytoskeletal organization, vesicular trafficking, formation of ruffled border and apoptosis [18–20].

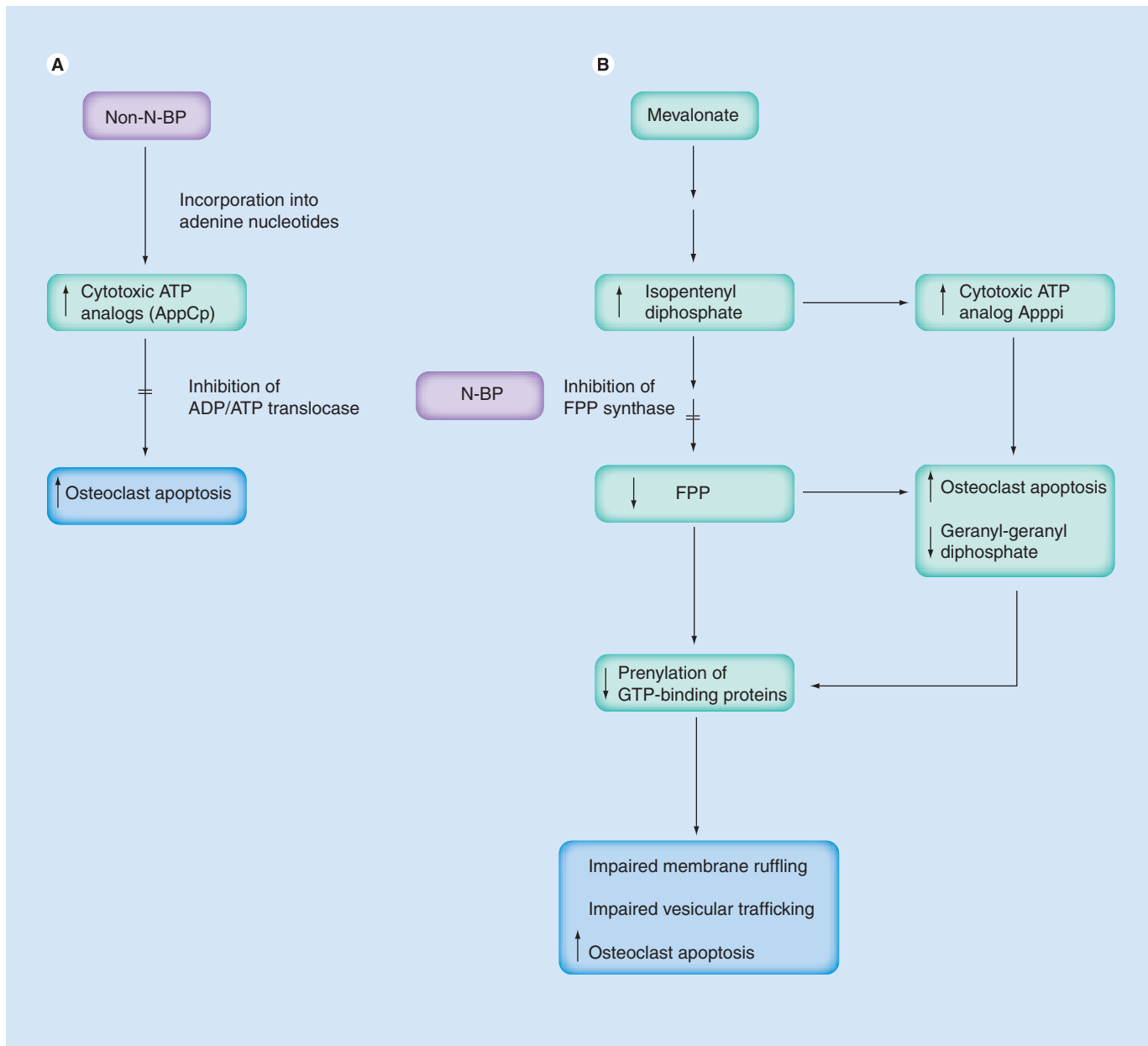


Figure 1. Mechanism of action of bisphosphonates. (A) Non-nitrogen-containing BPs are metabolized to cytotoxic ATP analogs, which initiate a cascade leading to osteoclast apoptosis. **(B)** Nitrogen-containing BPs interfere with the mevalonate pathway, mainly by inhibiting FPP synthase. Reduced prenylation of GTP-binding proteins impairs osteoclast function and leads to increased apoptosis. Inhibition of FPP synthase also results in accumulation of isopentenyl diphosphate, which may be metabolized to cytotoxic ATP analogs and directly stimulates apoptosis. BP: Bisphosphonate; FPP: Farnesyl diphosphate; N-BP: Nitrogen-containing BP; Non-N-BP: Non-nitrogen-containing BP.

Effect of BPs on growing bone

Bisphosphonates have the potential to bring about sizeable changes in bone density and the reshaping of vertebral bodies in children (FIGURE 2), since BPs interfere with the process by which the pediatric skeleton continually changes in bone size and shape (modeling). The bone tissue effect of BPs therapy on growing bone was first described by Rauch *et al.* in OI using intravenous (iv.), cyclical pamidronate administered every 2–4 months (total annual dose: 9 mg/kg/year). Through transilial histomorphometry, the investigators documented that treatment with pamidronate increased cortical thickness by interfering with modeling, whereby skeletal resorption was blunted by BP therapy on endocortical surfaces [21]. On the other hand, osteoblast activity on periosteal surfaces proceeded unfettered, giving rise to a sizeable net increase in the thickness of the internal and external cortices. These observations provide an explanation for the greater response in bone mineral density (BMD) and content (BMC) to BPs seen in children compared with adults.

Rauch *et al.* further described that the majority of the gains from pamidronate therapy in childhood OI are realized in the first 2–4 years, raising the question as to the optimal duration of therapy in the pediatric setting [22]. In patients with OI, gains in bone mass during therapy are maintained for at least 2 years after therapy has been stopped, although increases in areal spinal

BMD lag behind those in healthy controls post-treatment discontinuation. Furthermore, while bone resorption is elevated post-discontinuation compared with treated values, it is incompletely reactivated [23]. The effects of treatment discontinuation are more pronounced in growing patients [24]; for example, the differences between pamidronate-treated high-density bone and treatment-naive (post-discontinuation) bone in growing patients are clearly evident radiologically (FIGURE 3A & FIGURE 3B) compared with patients who ceased growth at the time of BP discontinuation (FIGURE 3C). It is not surprising then, that fractures have been described in OI patients following pamidronate discontinuation, precisely at the interface between the high-density (pamidronate-treated) and low-density (newly formed, pamidronate-naive) bone, raising the question as to the optimal dose as well as the duration of BP therapy.

These observations suggest that patients who have persistent risk factors for compromised bone health (such as a genetic defect such as collagenopathy) and who are still growing following a period of approximately 2–4 years of BP ‘rescue therapy’ (such as 9 mg/kg pamidronate per year, one of the most common dosing regimens in OI) [25] may require treatment that is continued as close to the cessation of linear growth as possible. This is particularly true if threats to bone health (either genetic or acquired) are persistent following treatment discontinuation. On the

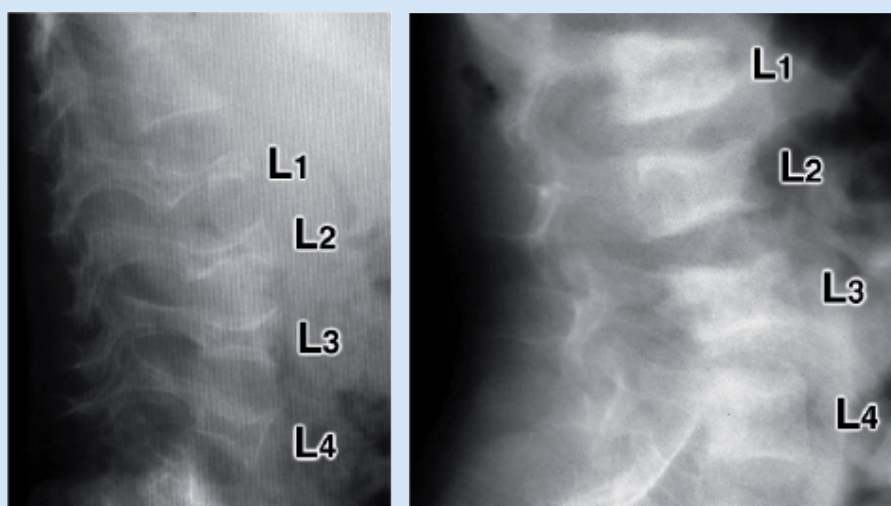


Figure 2. Lateral lumbar spine radiographs of two children of 3.3 years of age with osteogenesis imperfecta type III. The child in the left panel never received pamidronate, whereas the child in the right panel received 3 years of pamidronate therapy. Adapted with permission from [37].

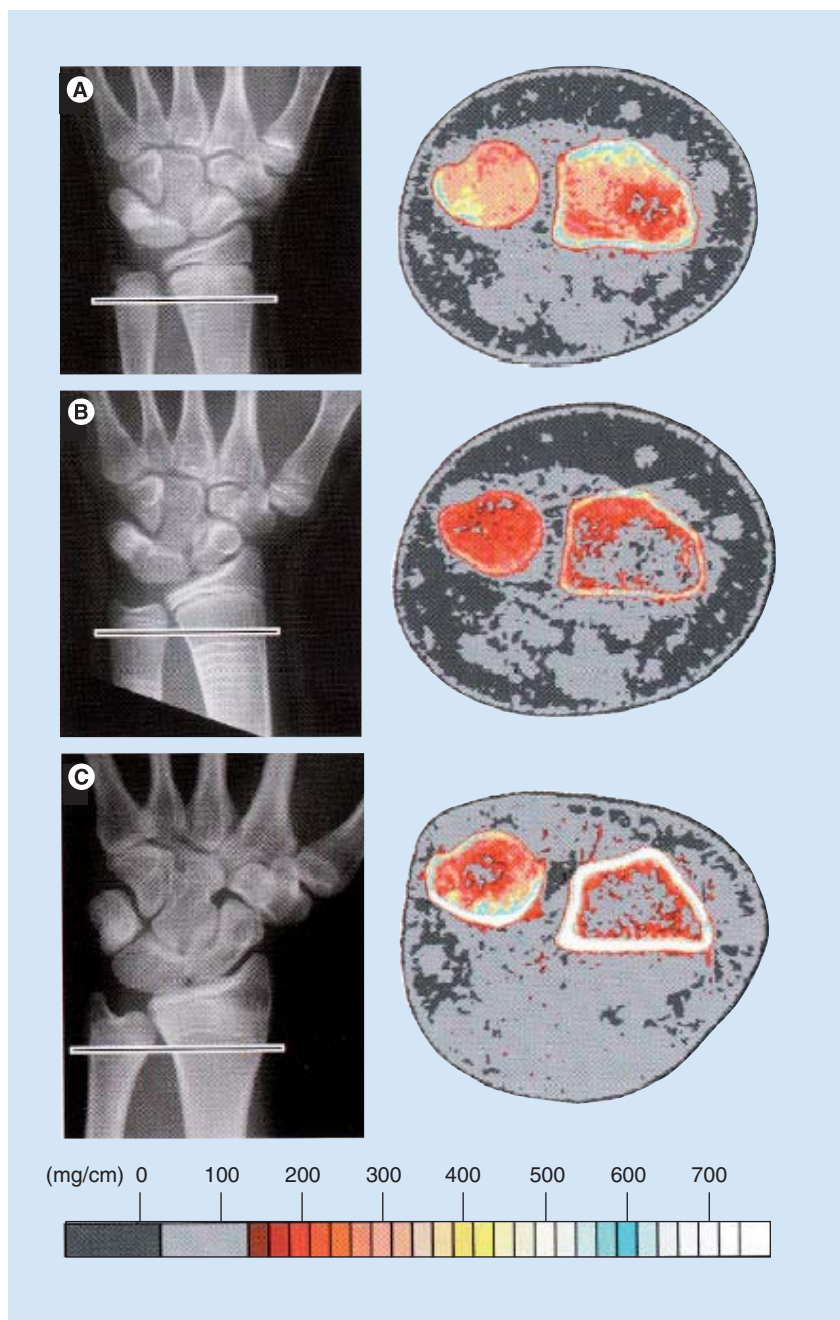


Figure 3. Radiographs of the distal forearm and wrist and corresponding pQCT images. The bar in the radiograph indicates the approximate site of the pQCT analysis. **(A)** Findings at the time of pamidronate discontinuation in a 12-year-old girl with osteogenesis imperfecta type IV. The patient received pamidronate cycles every 4 months for 6 years. Each treatment cycle led to the formation of a transverse line in the metaphysis. The BMC Z-score of the radius (the bone on the right side of the cross-sectional image) is +2.7. **(B)** Same patient as in (A) at 18 months following pamidronate discontinuation. Growth proceeded after treatment discontinuation. The pQCT section now presents bone that formed after the last cycle of pamidronate. The BMC Z-score is -2.7. **(C)** Man with osteogenesis imperfecta type 1 at 20 years of age, 2.2 years after pamidronate discontinuation. Pamidronate was started at the age of 14 years. The distal radius growth plate fused soon thereafter. Therefore, the metaphyseal lines do not reach the site of the pQCT analysis. Consequently, the BMC Z-score remained negative (-1.1) at the end of the pamidronate treatment. BMC: Bone mineral content; pQCT: Peripheral quantitative computed tomography. Adapted with permission from [24].

other hand, if the risk factors for osteoporosis (such as glucocorticoid therapy) have resolved at the time of BP discontinuation, there is at least theoretical potential for the creation of new, healthy bone of normal density through endochondral bone formation. This may obviate the need for ongoing therapy, a concept that requires validation through further study.

Evidence for the efficacy of BPs in children with specific disorders

■ Osteogenesis imperfecta

Bisphosphonates have been widely used in the treatment of moderate-to-severe OI in children, and more recently, less severe forms of OI (defined as two or fewer fractures per year, an absence of vertebral compression fractures and no long bone deformities) [26,27]. The first case report of beneficial effects of BP treatment in OI was published in 1987 [28] and was followed by a number of clinical trials that started in the 1990s. The results of over 30 clinical trials (most of them uncontrolled) conducted between 1997 and 2007 have been previously reviewed [8,29,30]. In these studies, the most commonly used BP was iv. pamidronate, administered at a dose of 0.6–3.75 mg/kg/day over 1–3 days in cycles every 1–6 months, with doses over 1 mg/kg administered every 4–6 months [25,31]. The age of the patients was 0.04–18 years and the duration of follow-up was up to 9 years. The reported therapeutic effects included improvement in bone density (increase in the lumbar spine BMD Z-score of approximately 2.6 or a change in spine BMD of 42–48%), grip strength, vertebral height, cortical thickness, trabecular number (but not trabecular thickness), decreased bone pain (within 1–2 weeks after the first infusion cycle), decreased bone turnover, increased mobility, improved quality of life and decreased fracture rate (by approximately 60% in children younger than 3 years). However, it was noted that the latter is difficult to interpret due to the natural decrease in the frequency of fractures in OI over time [8,25,32–38]. The increase in BMD and cortical thickness is most significant during the first 2 years of treatment, with smaller gains after prolonged treatment [21,39] and negligible gains after 4 years [40]. The factors that affect the response to BP treatment may be multifactorial. Early onset of treatment is particularly beneficial in patients with severe OI to prevent severe skeletal deformities and preserve mobility, but an increase in spine BMD Z-score does not seem to be associated with age at initiation of treatment, duration of treatment or initial spine BMD Z-score [41].

Other BPs that have been used in children with OI include: neridronate (iv.), zoledronic acid (iv.), olpadronate (oral) and alendronate (oral). A recent study has suggested that zoledronic acid may be as effective as pamidronate in the treatment of pediatric OI [42]. Neridronate infusions have been used in adults with OI [43] and more recently in children (2 mg/kg every 3 months) with a similar result – improvement in BMD and reduced fracture risk, particularly when started right after birth [6,44]. Olpadronate was used in two pediatric studies [45,46]. The latter was a randomized, double-blind, placebo-controlled trial. Oral treatment with olpadronate (10 mg/m²/day) resulted in a significant increase in lumbar BMD and a reduced fracture rate. Several small observational studies have evaluated the short-term benefits of oral alendronate (5–10 mg every 1–3 days) in improving BMD in children with OI and demonstrated improvement in collapsed vertebral bodies and mobility [47–51]. The increase in BMD Z-score was greatest in the lumbar spine (on average, an increase of 2.2–2.4 after 2–4 years of treatment) and to a lesser degree in forearm bones [47,50]. A partially randomized, controlled clinical trial that directly compared oral alendronate (1 mg/kg/day) with iv. pamidronate (3 mg/kg over 3 days every 4 months) over a 2-year period found similar effectiveness in terms of improvement in spine BMD (a 2.1 and 1.9 increase in Z-score, respectively), suppression of markers of bone turnover, fracture incidence and growth [48]. However, the largest trial assessing an oral agent (5 or 10 mg/day alendronate), in children with moderate-to-severe OI, showed an increase in lumbar spine BMD and a reduction in resorption parameters, but an absence of effect on clinically relevant parameters such as ilial cortical thickness, vertebral body area, pain and incident fractures [52].

In summary, short-term treatment with BPs has been proven to be beneficial in patients with OI and is becoming the standard of care in the treatment of moderate and severe forms. Proof of efficacy for outcomes including improved bone density, reduced fracture rate, decreased pain and improved quality of life has been provided by recent randomized, controlled trials (RCTs) [6,46,53,54]. The most published evidence showing beneficial effects exists to date for iv. pamidronate. The long-term outcome, which could be measured by the number of orthopedic procedures, decrease in long bone deformities and improvement of scoliosis in patients with OI treated with BPs remains unknown.

■ Chronic diseases

Systemic illnesses

Interest in the use of BPs for these indications has brought about a variety of approaches to the diagnosis of osteoporosis in children with chronic systemic illness. In children with OI, the diagnosis of their bone disorder is typically evident, due to the presence of physical stigmata that represent the hallmarks of the condition (blue sclerae, triangular facies, short stature, limb deformity and fractures). In children with chronic illness, the physical signs of osteoporosis are less evident, ranging from asymptomatic vertebral compression [55] to painful spine fractures/recurrent extremity fractures [56,57]. In view of the increased awareness of osteoporosis as a complication of chronic illness and the need for specific diagnostic criteria to guide clinicians beyond mere reductions in BMD or BMC, the International Society for Clinical Densitometry recently published a position statement on the matter, defining osteoporosis in childhood as ‘the presence of both a clinically significant fracture history and low BMC or BMD’. Low bone mass is defined as BMC or BMD Z-scores matched for age, gender and body size lower than 2 standard deviations (SD) below the mean [58]. The other component of the diagnosis, clinically significant fractures, is represented by at least one low trauma, lower extremity fracture, two or more upper extremity fractures or spontaneous vertebral compression. At the same time, it should be recognized that bone fragility can be present even if the BMC or BMD Z-scores are higher than -2 SD in children with serious illness such as leukemia [59]. Nevertheless, these criteria provide the clinician with a starting ground for identifying children with abnormal bone strength, and thereby considering their need for intervention. Note that in children, asymptomatic reductions in BMC or BMD are not sufficient to render a diagnosis of osteoporosis. On the other hand, vertebral compression is an under-recognized complication of chronic illness, occurring in 16 [55] and 19% [60] of children with acute lymphoblastic leukemia and rheumatic disorders, respectively.

The first step in treating children with osteoporosis due to systemic illness is to identify and treat modifiable risk factors by quelling the underlying disease, restoring the normal hormonal milieu (such as treating growth hormone and sex steroid deficiencies), treating vitamin D deficiency and rectifying under-/over-weight and physical deconditioning. However, these measures may be insufficient to rescue the child from

the frankly osteoporotic state. In such cases, intervention with a BP may be considered on compassionate grounds, as suggested in a recent *Cochrane Review* of BP use in a variety of systemic pediatric illnesses [61]. To date, there have been five RCTs [62–66] plus one follow-up study to an initial RCT [67] and three controlled trials [68–70] of BP use in children with chronic systemic illness. The *Cochrane Review* [61] showed the most frequent entry criterion for BP trials in children with chronic disease to be asymptomatic reductions in spine BMD. Of the agents studied, including oral alendronate, pamidronate (oral and iv.) and oral clodronate, iv. pamidronate was associated with the most consistent gains in BMC/BMD. There were no serious side effects of the treatment reported. Due to small numbers of patients in either group (<40), there was an inability to assess vertebral or extremity fracture prevention; other functional parameters including back pain and mobility were not evaluated. While admittedly it is extremely challenging to design osteoporosis trials in children that address the prevention of fractures (given the large numbers of children needed to carry out such trials), it is possible to enroll children with true osteoporosis (i.e., with vertebral compression fractures) and to evaluate the evolution of their bone and related morbidity beyond BMD, including muscle (grip) strength, mobility, vertebral morphometry and pain. Since treatment with iv. agents appears most promising in children with chronic illness, future RCTs carried out in as homogenous a patient population as possible with clinically relevant entry criteria (fractures) and end points are warranted.

Neuromuscular Disorders

Musculoskeletal complications that are encountered in several of the neuromuscular and metabolic diseases often represent a major source of morbidity. A better understanding of the fundamental mechanisms of bone pathology in these disorders will lead to a clearer understanding of how to treat the low bone mass seen in these patients, including when the use of BPs for a low bone mass and/or fractures is appropriate.

Several studies have been carried out examining BPs as a measure to augment bone density or decrease fractures in children with neuromuscular disease, as discussed in a recent review [71]. Most of this work has been carried out in children with neuromuscular dysfunction and bone loss secondary to cerebral palsy (CP). The main cause of a low bone density in this group of children and adolescents is lack of activity, but nutritional issues and pharmacological

treatments can also contribute. Efforts to initiate mechanical stimulation of their bones and to improve nutrition are helpful in these patients.

Cerebral palsy

One of the first double-blind, placebo-controlled clinical trials in patients with CP explored the safety and efficacy of iv. pamidronate to treat low bone mass in nonambulatory children [72]. Six pairs of subjects were matched for age, sex and race. One member of each pair randomly received plain saline placebo or pamidronate. Drug/placebo was administered intravenously daily for 3 consecutive days, and repeated at 3-month intervals for 1 year. Evaluations were continued for 6 months after the year of treatment. BMD was measured at the distal femur and lumbar spine. At the distal femur, BMD increased by $89 \pm 21\%$ (mean \pm SEM) over the 18-month study period in the pamidronate group compared with $9 \pm 6\%$ in controls. Age-normalized Z-scores also increased in the pamidronate group, but did not change significantly in the control group. The first dosing with pamidronate caused a transient drop in serum calcium that was asymptomatic; no other adverse effects were noted.

Other small, uncontrolled studies have tested the efficacy of iv. pamidronate in increasing BMD among nonambulatory children with CP [73–75] with improvements noted at the spine, femoral neck and/or total body. No serious side effects were noted. Bachrach *et al.* evaluated the response to pamidronate treatment among nine patients with spastic quadriplegic CP [76]. In keeping with other studies implementing iv. pamidronate in this setting, clinically significant Z-score gains were observed at the spine and distal femur. However, these gains were not maintained in all patients following treatment discontinuation – the mean spine BMD Z-score close to 3 years post-treatment approached the pretreatment value. A total of six of eight patients had distal femur Z-scores that were the same or improved compared with baseline, at approximately 2 years following treatment discontinuation. While most, but not all, gains in BMD were lost over the first 2 years following treatment discontinuation, no patient sustained fractures during or after therapy [76].

Muscular dystrophy

A recent case series of three boys with muscular dystrophy showed a beneficial skeletal effect of once weekly oral alendronate, in addition to calcium and vitamin D supplementation [77].

In another small before–after trial of boys with Duchenne muscular dystrophy receiving glucocorticoid therapy, the mean age was 10.8 years (range: 6.9–15.6 years) and each had a known low BMD, alendronate had a positive effect on BMD Z-scores. In a multivariable analysis, improvement in total body and spine Z-scores was associated with younger age at baseline ($p = 0.01$ for both). These data suggest that the effect of these agents may be greatest when given early in the course of the disease [78].

■ Idiopathic juvenile osteoporosis

Idiopathic juvenile osteoporosis (IJO) is a term relegated to otherwise healthy children with unexplained low bone mass that is characterized by increased fracture rates [79]. Many pediatric providers are unfamiliar with this condition, owing to difficulty in recognition and since bone fragility in a child generates an extensive differential diagnosis. IJO is a diagnosis of exclusion. Children often present with back or other bone pain, recurrent fractures, or osteopenia on radiographs or dual-energy x-ray absorptometry (DXA) assessments. Trabecular deficits are marked and histomorphometric studies have shown a decreased bone formation rate along the endocortical surface [80,81]. Many of the reports of BP use for IJO include data from heterogeneous case series that include patients with osteoporosis from varying etiologies. One case report using iv. pamidronate every 3 months resulted in dramatic gains (>20%) in BMD and a reduced fracture rate [82]. In another small case series of six patients with IJO, an almost twofold increase in spinal BMD Z-score was observed [83]. A recent case report showed improvement of BMD and reduced fractures upon institution of parenteral clodronate in an 8-year-old boy with severe IJO [84]. Upon discontinuation of therapy, bone pain and fractures recurred within 1 year. Of note is the fact that many cases of IJO resolve spontaneously, making interpretation of clinical outcomes in response to BP therapy difficult to interpret.

Overview of short- & long-term safety issues

■ Short-term safety

Hypocalcemia

A transient decrease in serum calcium and phosphorus, and a transient increase in parathyroid hormone have been reported in children treated with iv. pamidronate [25,85]. The risk of hypocalcemia can be reduced by maintenance of a normal vitamin D status and ongoing provision of adequate calcium and vitamin D supplementation

while on therapy. Munns *et al.* have advocated for treatment of all children aged 4 years of age and older with 0.25 µg calcitriol twice daily, and 1000 mg elemental calcium twice daily for the first 3 days post-infusion of zoledronic acid [86]. However, the safety and efficacy of this regimen is still under study.

Acute-phase reaction

An acute-phase reaction, including influenza-like symptoms such as low-grade fever, headache, nausea, vomiting, rash, tachycardia, myalgia and bone pain, may occur upon first exposure to iv. and oral BPs. The reaction, occurring in the majority of patients, usually occurs within 48 h of administration and is typically brief, lasting less than 24 h [25,87–90]. These symptoms may be accompanied by a mild reduction in absolute lymphocyte counts [89]. The symptoms have been attributed to release of proinflammatory cytokines by T cells [91,92]. Practitioners frequently administer antipyretic/anti-inflammatory agents to mitigate the side effects resulting from the acute-phase reaction. For pamidronate, the reaction can also be lessened by administering one half the dose for the initial infusion.

Nephrotoxicity

Nephrotoxicity has been reported in adults treated with pamidronate [93,94]. No adverse effect on renal function has been reported in children treated with pamidronate or other BPs, although it would be prudent to use BPs with caution in patients with renal insufficiency, monitoring renal function closely.

Gastrointestinal toxicity

Orally-administered N-BPs may cause esophageal irritation and ulceration [95]. Gastrointestinal toxicity can be avoided by swallowing the tablet with a full glass of water on an empty stomach before breakfast and remaining upright for at least 30 min thereafter.

Ocular toxicity

Anterior uveitis has been reported in patients treated with pamidronate and alendronate [96–98]. Uveitis has also been observed in two out of 215 children treated with pamidronate [29]. Patient outcome following identification of uveitis was not reported.

Atrial fibrillation

In adults, atrial fibrillation (AF) and flutter has been reported in patients receiving both oral alendronate and risedronate, and parenteral

zoledronic acid [30,99,100]. One case series from the UK reported reassuring age-adjusted incidence rate ratios for these arrhythmias in individuals during their exposure to oral BPs (n = 2195) to be 1.07 (95% confidence interval [CI]: 0.94–1.21). The age-adjusted incidence rate ratios for alendronate (n = 1489) and risedronate (n = 649) in exposed individuals were 1.09 (95% CI: 0.93–1.26) and 0.99 (95% CI: 0.78–1.26) respectively. However, in *post-hoc* analyses, an increased risk of incident AF or flutter was detected for patients during their first few months of alendronate therapy [100]. A recent US study examined alendronate ever use in relation to the risk of incident AF in women in a clinical practice setting. They identified 719 women with incident AF and 966 female control subjects without AF who were frequency matched on age, presence or absence of treated hypertension and calendar year. More AF case patients than controls had ever used alendronate (6.5 [n = 47] vs 4.1% [n = 40]; p = 0.03). Compared with never use of any BP, ever use of alendronate was associated with a higher risk of incident AF (odds ratio: 1.86; 95% CI: 1.09–3.15) after adjustment for the matching variables, a diagnosis of osteoporosis and a history of cardiovascular disease. Based on the population-attributable fraction, they estimated that 3% of incident AF in this population might be explained by alendronate use [99]. Of note, there have been no reports to date of atrial or other arrhythmias in children receiving either oral or parenteral BPs.

Anaphylactic reactions

There is a theoretical risk of anaphylaxis in response to a parenteral BP. The risk is extremely low, and may be higher in children with rheumatic diseases owing to underlying inflammation [101].

■ Long-term safety

Bisphosphonates are rapidly taken up and deposited in the skeleton. A half-life of more than 10 years has been reported in adults [102]. BPs may also be released from the skeleton due to bone turnover [103]. Long-term release of BPs has been shown in children who were treated with pamidronate for 4–10 years [104]; pamidronate was detectable in the urine up to 8 years after discontinuation of treatment. Incomplete reactivation of resorption was reported 2 years after discontinuation of pamidronate treatment in children [23], suggesting continued biologic activity of the drug for at least 2 years after the drug was last given.

Teratogenicity

Despite a known, minimal theoretical risk, there have been no human reports to date of an adverse effect of BPs when administered either preconception or during pregnancy, likely because the amount of BP that is mobilized from the skeleton in subsequent years is clinically insignificant. For example, data from Papapoulos and Cremers shows that 4–10 years after daily oral pamidronate administration to children with osteoporosis, a maximum of 0.13 mg/kg/year is excreted in the urine (less than 0.02% of the annual dose) [104]. The fact that the amount released from the skeleton is clinically insignificant is supported by numerous human reports of BP administration preconception/during pregnancy and newborn outcome. Recent studies, including a comprehensive literature review on adolescent girls and women who have received BP agents either preconception or during pregnancy, do not show adverse outcomes on the newborn [105,106]. In fact, a 2008 report by Levy *et al.* [106] and another by Djokanovic *et al.* [105] have arisen from the Motherisk program at the Toronto Hospital for Sick Children (ON, Canada). In the study by Levy *et al.* [106], 21 women exposed to BPs during or less than 3 months before pregnancy were compared with 21 matched controls; no adverse effects on the mothers or infants were found. This study concluded that: “coupled with the existing data in the literature, our findings suggest that preconceptual and first-trimester use of BPs may not pose substantial fetal risks”. Similarly, the article by Djokanovic *et al.* [105] provides a review of all case reports to December 2008 of women or girls who have received BPs preconception or during pregnancy, and reports an absence of skeletal abnormalities or congenital malformations in the infants. This review concludes: “although in theory BPs may affect bone modeling and development in the fetus, the 51 cases reported to date did not detect such pathology”.

Other reports include those on two pregnancies after exposure to pamidronate shortly before conception, with transient hypocalcemia on day 1 in one of the newborns, but no adverse effect was observed on the skeleton or congenital anomalies that were felt to be attributable to the drug [107]. Another case report highlights the course of a 33-year-old female who received zoledronic acid throughout the second and third trimesters of pregnancy, in addition to other chemotherapeutic agents, as the patient was not aware of the pregnancy until the 28th

week [108]. A healthy female infant was delivered at 35 weeks and exhibited no side effects at 12 months. Another report describes the uneventful pregnancies, deliveries and infant outcomes of two women with OI who received iv. pamidronate prior to conception [107]. Both infants inherited OI – one manifested type I while the other had type iv. and bilateral talipes equinovarus. At the time of the report, both children remained well and free of fracture for 14 and 16 months postpartum.

Metaphyseal bands ('zebra lines')

Children treated with pamidronate develop characteristic radiographic features referred to as metaphyseal bands, which are transverse lines of increased density in the metaphysis and correspond to the treatment cycles [25,28,83,109,110]. Metaphyseal lines are thought to represent a mixture of unresorbed calcified cartilage and bone. Resorption of these lines occurs over time, but cartilaginous remnants may remain in trabeculae and the cortical bone of the metaphysis [25,83,109–112]. Presence of these sclerotic lines does not seem to be of functional significance and the separation between the lines suggests that interval growth of the growth plate occurs during therapy.

Iatrogenic osteopetrosis

Iatrogenic osteopetrosis was reported in a 12-year-old boy who was treated with higher than recommended doses of pamidronate (2.2–3.4 mg/kg every 3 weeks and then at less frequent intervals) for idiopathic bone pain and a marked elevation of alkaline phosphatase [113]. He was treated with pamidronate between 7.75 and 10.5 years of age. He was later re-evaluated at the age of 17 years, over 6 years post-exposure to pamidronate [114]. Interval fractures had occurred. Modeling disturbances consistent with osteopetrosis persisted, but partial recovery was demonstrated by the presence of a unique concave shape along metaphyseal surfaces. The metaphyseal osteosclerosis that was noted at this patient's presentation had remodeled to become focal areas of dense, diaphyseal bone. These findings suggest that BP toxicity during childhood can impair skeletal modeling and remodeling, with effects persisting into young adulthood. These reports highlight the skeletal effects that may arise from toxic doses of BP therapy. Therefore, it is recommended that BPs be administered by experts in the care of children with bone diseases, at published doses associated with a favorable side effect profile (such as 9 mg/kg/year pamidronate or lower).

Fractures after BP discontinuation in growing patients

The effect of BPs on bone geometry and mechanical properties in the long-term remains under study. There is also concern about potential continued suppression of bone turnover after discontinuation of BPs. In fact, bone stiffness could potentially make it more brittle, which has been observed in a mouse model of OI treated with alendronate [115]. Persistence of mineralized growth plate cartilage may make the skeleton less resistant to fractures [113,116]. As discussed previously in this review, there appears to be a zone of susceptibility to fracture at the interface between previously treated and iv. BP (pamidronate) naive bone that occurs following BP discontinuation in OI [117], with recommendations to minimize the discrepancy in bone quality/density at this interface.

Fracture healing

While spontaneous fracture healing is not impaired, healing may be delayed at osteotomy sites [118,119]. It has been recommended that BPs are discontinued 6 months prior to elective orthopedic procedures [120]; however, this may interfere with the children's ability to arrest the fracture–refracture cycle and augment bone mass/density/mobility preoperatively. At the very least, it is recommended that BPs are delayed in their administration post-operatively, until radiographic signs of osteotomy healing are evident.

Growth

Studies in mouse models of OI have shown an adverse effect of alendronate on linear bone growth with persistence of metaphyseal calcified cartilage [121,122]. Longitudinal growth does not seem to be impaired during BP treatment in children at recommended doses, and may even improve [47,50,51,109]. A total of 4 years of treatment with pamidronate resulted in height gain over that expected for untreated patients based on historical controls in patients with moderate-to-severe OI [123].

Esophageal cancer

In adults, there have been rare reports of esophageal cancer associated with BP use, as was recently reviewed in the *New England Journal of Medicine* [124]. Since the initial marketing of alendronate in 1995 to mid-May 2008, 23 cases of esophageal cancer have been reported to the US FDA; oral alendronate being the suspect drug in 21 of those cases. The median age of

those affected was 74.0 years and eight deaths were reported. To date, there have been no reported cases in children or adolescents.

Osteonecrosis of the jaw

Osteonecrosis of the jaw (ONJ) has been reported in several series in adults [125–127]. Risk factors included length of treatment, dental procedures, age over 60 years, female sex, the type of BP (with higher risk after administration of zoledronate vs pamidronate) and history of multiple myeloma. There have been no reported cases of ONJ in children after treatment with BPs, even in those with a history of dental surgical procedures after 0.03–7.9 years of treatment [128]. However, there remains significant anxiety with respect to this potential problem. The ongoing collection of safety data in pediatric patients will be particularly informative.

Recommendations for the use of BPs in children

■ Candidates for therapy

In many centers worldwide, BP administration, particularly iv., to children with moderate and severe forms of OI has been adopted as part of routine clinical care. This practice has arisen from over 15 years of experience with these agents in this condition. Such an approach appears well justified, provided these drugs are administered by experts in the care of children with OI, at published doses, and as part of multidisciplinary rehabilitative care. For children with mild forms of OI or osteoporosis due to chronic illness, the evidence to date suggests that the use of BPs should be relegated to well-designed clinical trials or used on compassionate grounds for such children who, in addition, show clinical evidence for bone fragility (recurrent low trauma extremity fractures and/or vertebral compression) associated with low bone mass or density. At the present time, there are insufficient data on the use of BPs as preventative agents to recommend their administration to children with asymptomatic reductions in bone mass/density alone. For apparently healthy children with recurrent fractures, the priority is first to rule out the possibility of an underlying chronic illness or type I collagenopathy predisposing to the bone fragility. If there is no evidence of any underlying systemic condition (such as Crohn's disease) or OI, BPs are generally not indicated unless the recurrent, low-trauma fractures are associated with clinically significant reductions in bone mass/density more than 2 SD below the mean).

■ Dose, route of administration & duration of therapy

To date, there is no consensus on the optimal agent, dosage or duration of therapy. In the absence of numerous randomized, controlled trials comparing different agents, doses and durations in various bone disorders, it is impossible to state whether one treatment protocol is more efficacious than another. On balance, the response to iv. agents [6,44,53,68,72] appears to be more consistently positive than oral agents [46,54,62–64,66,69] in the context of randomized and controlled trials, although one short-term RCT on a small number of OI patients has shown equal efficacy between oral alendronate and iv. pamidronate [48]. When considering the duration of therapy, evidence from the OI literature suggests that maximal gains from iv. pamidronate occur in the first 2–4 years of therapy; children who have not yet ceased linear growth appear to be at risk for being unable to maintain the gains that have been realized in this initial treatment period. To date, there are no randomized trials to guide the clinician following the initial 2–4 years of BP therapy given to stabilize the osteoporosis. However, children may benefit from longer-term BP therapy, if risk factors persist, in order to preserve the gains realized in the rescue therapy phase, and to prevent long bone fractures from occurring at the interface between cyclical BP-treated and BP-naïve bone. This approach must be weighed on an individual basis against observations of significant reductions in bone turnover and/or bone density results that are increased above clinically acceptable end points (i.e., above average).

■ Monitoring

To date, the pediatric bone health field has largely focused on BMD, most frequently obtained by DXA, as the main outcome in the course of clinical trials. However, attention to spinal health and other functional indices such as pain, fractures, quality of life, mobility and muscle strength also merit attention in both clinical care and research studies. Since large numbers of patients are required to demonstrate a reduction in incident fractures during clinical trials, fracture rates may not always be a feasible end point in pediatric studies, where the number of eligible patients is clearly smaller compared with adults. On the other hand, spine morphometry, pain, quality of life, mobility and muscle strength are readily quantifiable in children. Bone histomorphometry remains the gold

standard for skeletal assessment and is advised, wherever possible, as an effective tool to monitor the response to BP therapy at the bone tissue level, such as during the course of clinical trials. Bone biomarkers of resorption (such as urinary

N-telopeptides) are useful to document the antiresorptive action of BPs on bone, and they provide an indication of medication compliance and absorption. In addition, peripheral quantitative computed tomography is increasingly

Executive summary

Structure of bisphosphonates & mechanisms of action on bone

- Bisphosphonates (BPs) are chemical analogs of pyrophosphate, in which the oxygen atom is replaced by a carbon atom (P-C-P instead of P-O-P). By adhering to the bone surface, BPs come into close contact with osteoclasts, where they exert their therapeutic actions.
- The R1 side chain of BPs is usually a hydroxyl group, which, along with the phosphate groups, acts to increase the affinity for skeletal calcium.
- The R2 side chain modifications determine the antiresorptive potency of BPs. Introduction of the nitrogen atom at R2 (pamidronate, alendronate, ibandronate, neridronate and olpadronate), particularly within a heteroaromatic ring (zoledronate and risedronate), increases the *in vitro* antiresorptive potency.

Effect of bisphosphonates on growing bone

- Bisphosphonates have the potential to bring about sizeable changes in bone density and the reshaping of vertebral bodies in children.
- A greater response to BPs in bone mineral density (BMD) and content is seen in children compared with adults, since the cortical surfaces of bone thicken as the BP interferes with modeling, while skeletal resorption is blunted along endocortical surfaces.
- The majority of the gains from BP therapy in childhood osteogenesis imperfecta (OI), a pediatric disease for which BPs are commonly prescribed, are realized in the first 2–4 years, raising the question as to the optimal duration of therapy in the pediatric setting.

Evidence for the efficacy & safety of bisphosphonates in children with specific disorders

- Bisphosphonates have been widely used in children with OI. Reported therapeutic effects include improvement in bone density, grip strength, vertebral height, cortical thickness, trabecular number, quality of life and mobility, decreased bone pain, bone turnover and fracture rate.
- The first step in treating children with osteoporosis owing to systemic illness is to identify and treat modifiable risk factors by quelling the underlying disease, restoring the normal hormonal milieu (e.g., growth hormone and sex steroid status), treating vitamin D deficiency and rectifying under-/over-weight and physical deconditioning. However, if these measures are insufficient, consideration of treatment with a BP is warranted for those with low BMD or bone mineral content and bone fragility.
- In neuromuscular diseases, most of the clinical studies examining the use of BPs have been carried out in children with bone fragility or low BMD that is secondary to cerebral palsy. Both randomized clinical trials and small, uncontrolled studies have tested the efficacy of intravenous pamidronate in increasing BMD among nonambulatory children with cerebral palsy and have noted skeletal gains at the spine, femoral neck and/or total body and the absence of serious side effects.
- There is a lack of consensus regarding use of BPs in idiopathic juvenile osteoporosis. Complicating the issue is the fact that many of the reports of BP use for idiopathic juvenile osteoporosis include data from heterogeneous case series that include patients with osteoporosis from varying etiologies.

Short-term safety issues

- Transient hypocalcemia is a common, short-term side effect following intravenous BP therapy. However, the risk of this problem can be reduced by maintenance of a normal vitamin D status and ongoing provision of adequate calcium and vitamin D supplementation during therapy.
- A brief acute-phase reaction, including influenza-like symptoms such as low-grade fever, headache, nausea, vomiting, rash, tachycardia, myalgia and bone pain may occur upon first exposure to intravenous and oral BPs.
- Esophageal irritation is a common side effect after the use of oral BPs that can be minimized by taking the medication on an empty stomach and staying upright for 30 min following drug administration.
- Uncommon short-term safety issues are nephrotoxicity, anterior uveitis and atrial fibrillation.

Long-term safety issues

- Bisphosphonates have an extremely long half-life, evidenced by long-term release of BPs, that has been demonstrated in children who were treated with pamidronate 4–10 years previously.
- Potential long-term side effects include radiographic metaphyseal bands, iatrogenic osteopetrosis, fractures after BP discontinuation in growing children, delayed healing at osteotomy sites, esophageal cancer and osteonecrosis of the jaw. It is noteworthy that no cases of some of these adverse effects (e.g., esophageal cancer and osteonecrosis of the jaw) have been seen in children.

Recommendations for the use of bisphosphonates in children

- Bisphosphonate administration, particularly intravenous, in children with moderate and severe forms of OI has been adopted as part of routine clinical care.
- For children with mild forms of OI or osteoporosis owing to chronic illness, the evidence to date suggests that the use of BPs should be relegated to well-designed clinical trials or used on compassionate grounds for such children who, in addition, show clinical evidence for bone fragility associated with low bone mass or density.
- At the present time, there are insufficient data on the use of BPs as preventative agents to recommend their administration to children with asymptomatic reductions in bone mass/density alone.

used in the pediatric clinical setting, since this three-dimensional technique overcomes the issue of bone size that clouds DXA areal BMD measures, and assesses not only bone density but also bone geometry, another important parameter that confers bone strength, and does so at frequent sites of fractures (distal radius and tibia) [129–131].

Future perspective

Clinical experience with BPs in pediatric patients is growing, with benefits to quality of life demonstrated in OI. While longer-term safety data in OI are accumulating, there remains a paucity of such information in children with other bone disorders. Well-designed trials assessing different agents, dose and duration, with rigorous collection of both safety and efficacy end points are needed, particularly in children with non-OI osteoporosis. Gaps also remain in knowledge regarding nutritional and activity interventions that may augment the strength of a young growing skeleton, in addition to potential skeletal gains afforded by a BP. To document the long-term effects of BP therapy administered to children, the creation of bone health registries is a mechanism that merits attention in future research efforts. Meanwhile, cautious use of these medications in children with chronic illness osteoporosis is warranted, and only for children or adolescents with both reductions in BMD or BMC and clinical evidence for quality of life-limiting

skeletal fragility. Finally, whether in the context of clinical trials or in routine clinical care, BPs should be administered to children by experts in their prescription and in monitoring of the relevant clinical outcomes.

Author note

This review was developed by the Drugs and Therapeutics Committee of the Lawson Wilkins Pediatric Endocrine Society to be of educational value for practitioners. It does not indicate an official policy or guideline of the Society.

Acknowledgements

The authors would like to acknowledge Victor Konji for his assistance in the preparation of the manuscript. Dr Ward is supported by a Canadian Child Health Clinician Scientist Career Enhancement Award and by the Canadian Institutes for Health Research New Investigator Program. Dr Gordon is supported by Project 5-T71-MC-00009–14 from the Maternal and Child Health Bureau.

Financial & competing interests disclosure

Dr Ward has been a consultant to Novartis in the past 2 years and has previously participated in investigator-initiated and sponsored trials of alendronate (Merck Frost). The authors have no other relevant affiliations or financial involvement with any organization or entity with a financial interest in or financial conflict with the subject matter or materials discussed in the manuscript apart from those disclosed.

No writing assistance was utilized in the production of this manuscript.

Bibliography

Papers of special note have been highlighted as:

▪ of interest

- Russell RG: Bisphosphonates: mode of action and pharmacology. *Pediatrics* 119(Suppl. 2), S150–S162 (2007).
- Review of the mechanism of action of bisphosphonates.**
- Fleisch H, Russell RG, Francis MD: Diphosphonates inhibit hydroxyapatite dissolution *in vitro* and bone resorption in tissue culture and *in vivo*. *Science* 165(899), 1262–1264 (1969).
- Azuma Y, Sato H, Oue Y *et al.*: Alendronate distributed on bone surfaces inhibits osteoclastic bone resorption *in vitro* and in experimental hypercalcemia models. *Bone* 16(2), 235–245 (1995).
- Suda T, Nakamura I, Jimi E, Takahashi N: Regulation of osteoclast function. *J. Bone Miner. Res.* 12(6), 869–879 (1997).
- Shaw NJ, Bishop NJ: Bisphosphonate treatment of bone disease. *Arch. Dis. Child.* 90(5), 494–499 (2005).
- Gatti D, Antoniazzi F, Prizzi R *et al.*: Intravenous neridronate in children with osteogenesis imperfecta: a randomized controlled study. *J. Bone Miner. Res.* 20(5), 758–763 (2005).
- Green JR, Muller K, Jaeggi KA: Preclinical pharmacology of CGP 42'446, a new, potent, heterocyclic bisphosphonate compound. *J. Bone Miner. Res.* 9(5), 745–751 (1994).
- Speiser PW, Clarson CL, Eugster EA *et al.*: Bisphosphonate treatment of pediatric bone disease. *Pediatr. Endocrinol. Rev.* 3(2), 87–96 (2005).
- Review of bisphosphonate treatment in children.**
- Widler L, Jaeggi KA, Glatt M *et al.*: Highly potent geminal bisphosphonates. From pamidronate disodium (Aredia) to zoledronic acid (Zometa). *J. Med. Chem.* 45(17), 3721–3738 (2002).
- Bachrach LK, Ward LM: Clinical review: bisphosphonate use in childhood osteoporosis. *J. Clin. Endocrinol. Metab.* 94(2), 400–409 (2009).
- Luckman SP, Hughes DE, Coxon FP, Graham R, Russell G, Rogers MJ: Nitrogen-containing bisphosphonates inhibit the mevalonate pathway and prevent post-translational prenylation of GTP-binding proteins, including Ras. *J. Bone Miner. Res.* 13(4), 581–589 (1998).
- van Beek E, Pieterman E, Cohen L, Lowik C, Papapoulos S: Nitrogen-containing bisphosphonates inhibit isopentenyl pyrophosphate isomerase/farnesyl pyrophosphate synthase activity with relative potencies corresponding to their antiresorptive potencies *in vitro* and *in vivo*. *Biochem. Biophys. Res. Commun.* 255(2), 491–494 (1999).
- Green JR: Bisphosphonates: preclinical review. *Oncologist* 9(Suppl. 4), 3–13 (2004).

- 14 Rogers MJ, Brown RJ, Hodkin V, Blackburn GM, Russell RG, Watts DJ: Bisphosphonates are incorporated into adenine nucleotides by human aminoacyl-tRNA synthetase enzymes. *Biochem. Biophys. Res. Commun.* 224(3), 863–869 (1996).
- 15 Heiskanen KM, Bhat MB, Wang HW, Ma J, Nieminen AL: Mitochondrial depolarization accompanies cytochrome c release during apoptosis in PC6 cells. *J. Biol. Chem.* 274(9), 5654–5658 (1999).
- 16 Lehenkari PP, Kellinsalmi M, Napankangas JP *et al.*: Further insight into mechanism of action of clodronate: inhibition of mitochondrial ADP/ATP translocase by a nonhydrolyzable, adenine-containing metabolite. *Mol. Pharmacol.* 61(5), 1255–1262 (2002).
- 17 Zhang FL, Casey PJ: Protein prenylation: molecular mechanisms and functional consequences. *Annu. Rev. Biochem.* 65, 241–269 (1996).
- 18 Ridley AJ, Paterson HF, Johnston CL, Diekmann D, Hall A: The small GTP-binding protein Rac regulates growth factor-induced membrane ruffling. *Cell* 70(3), 401–410 (1992).
- 19 Zhang D, Udagawa N, Nakamura I *et al.*: The small GTP-binding protein, rho p21, is involved in bone resorption by regulating cytoskeletal organization in osteoclasts. *J. Cell Sci.* 108(Part 6), 2285–2292 (1995).
- 20 Monkkonen H, Auriola S, Lehenkari P *et al.*: A new endogenous ATP analog (AppI) inhibits the mitochondrial adenine nucleotide translocase (ANT) and is responsible for the apoptosis induced by nitrogen-containing bisphosphonates. *Br. J. Pharmacol.* 147(4), 437–445 (2006).
- 21 Rauch F, Travers R, Plotkin H, Glorieux FH: The effects of intravenous pamidronate on the bone tissue of children and adolescents with osteogenesis imperfecta. *J. Clin. Invest.* 110(9), 1293–1299 (2002).
- **Analysis of the bone tissue effects of pamidronate in children with osteogenesis imperfecta.**
- 22 Rauch F, Travers R, Glorieux FH: Pamidronate in children with osteogenesis imperfecta: histomorphometric effects of long-term therapy. *J. Clin. Endocrinol. Metab.* 91(2), 511–516 (2006).
- 23 Rauch F, Munns C, Land C, Glorieux FH: Pamidronate in children and adolescents with osteogenesis imperfecta: effect of treatment discontinuation. *J. Clin. Endocrinol. Metab.* 91(4), 1268–1274 (2006).
- 24 Rauch F, Cornibert S, Cheung M, Glorieux FH: Long-bone changes after pamidronate discontinuation in children and adolescents with osteogenesis imperfecta. *Bone* 40(4), 821–827 (2007).
- **Specific effects of bisphosphonate treatment discontinuation in children.**
- 25 Glorieux FH, Bishop NJ, Plotkin H, Chabot G, Lanoue G, Travers R: Cyclic administration of pamidronate in children with severe osteogenesis imperfecta. *N. Engl. J. Med.* 339(14), 947–952 (1998).
- 26 Glorieux FH: Treatment of osteogenesis imperfecta: who, why, what? *Horm. Res.* 68(Suppl. 5), 8–11 (2007).
- 27 Land C, Rauch F, Travers R, Glorieux FH: Osteogenesis imperfecta type VI in childhood and adolescence: effects of cyclical intravenous pamidronate treatment. *Bone* 40(3), 638–644 (2007).
- 28 Devogelaer JP, Malghem J, Maldague B, Nagant de Deuxchaisnes C: Radiological manifestations of bisphosphonate treatment with APD in a child suffering from osteogenesis imperfecta. *Skeletal Radiol.* 16(5), 360–363 (1987).
- 29 Rauch F, Glorieux FH: Osteogenesis imperfecta. *Lancet* 363(9418), 1377–1385 (2004).
- **Outstanding review of the diagnosis and treatment of osteogenesis imperfecta (OI).**
- 30 Castillo H, Samson-Fang L: Effects of bisphosphonates in children with osteogenesis imperfecta: an AACPD systematic review. *Dev. Med. Child Neurol.* 51(1), 17–29 (2009).
- 31 DiMeglio LA, Ford L, McClintock C, Peacock M: Intravenous pamidronate treatment of children under 36 months of age with osteogenesis imperfecta. *Bone* 35(5), 1038–1045 (2004).
- 32 Astrom E, Jorulf H, Soderhall S: Intravenous pamidronate treatment of infants with severe osteogenesis imperfecta. *Arch. Dis. Child.* 92(4), 332–338 (2007).
- 33 Falk MJ, Heeger S, Lynch KA *et al.*: Intravenous bisphosphonate therapy in children with osteogenesis imperfecta. *Pediatrics* 111(3), 573–578 (2003).
- 34 Glorieux FH: Experience with bisphosphonates in osteogenesis imperfecta. *Pediatrics* 119(Suppl. 2), S163–S165 (2007).
- 35 Lowing K, Astrom E, Oscarsson KA, Soderhall S, Eliasson AC: Effect of intravenous pamidronate therapy on everyday activities in children with osteogenesis imperfecta. *Acta Paediatr.* 96(8), 1180–1183 (2007).
- 36 Montpetit K, Plotkin H, Rauch F *et al.*: Rapid increase in grip force after start of pamidronate therapy in children and adolescents with severe osteogenesis imperfecta. *Pediatrics* 111(5 Part 1), E601–E603 (2003).
- 37 Munns CF, Rauch F, Travers R, Glorieux FH: Effects of intravenous pamidronate treatment in infants with osteogenesis imperfecta: clinical and histomorphometric outcome. *J. Bone Miner. Res.* 20(7), 1235–1243 (2005).
- 38 Plotkin H, Rauch F, Bishop NJ *et al.*: Pamidronate treatment of severe osteogenesis imperfecta in children under 3 years of age. *J. Clin. Endocrinol. Metab.* 85(5), 1846–1850 (2000).
- 39 Rauch F, Plotkin H, Zeitlin L, Glorieux FH: Bone mass, size, and density in children and adolescents with osteogenesis imperfecta: effect of intravenous pamidronate therapy. *J. Bone Miner. Res.* 18(4), 610–614 (2003).
- 40 Land C, Rauch F, Glorieux FH: Cyclical intravenous pamidronate treatment affects metaphyseal modeling in growing patients with osteogenesis imperfecta. *J. Bone Miner. Res.* 21(3), 374–379 (2006).
- 41 Bajpai A, Kabra M, Gupta N, Sharda S, Ghosh M: Intravenous pamidronate therapy in osteogenesis imperfecta: response to treatment and factors influencing outcome. *J. Pediatr. Orthop.* 27(2), 225–227 (2007).
- 42 Brown JJ, Zacharin MR: Safety and efficacy of intravenous zoledronic acid in paediatric osteoporosis. *J. Pediatr. Endocrinol. Metab.* 22(1), 55–63 (2009).
- 43 Adami S, Gatti D, Colapietro F *et al.*: Intravenous neridronate in adults with osteogenesis imperfecta. *J. Bone Miner. Res.* 18(1), 126–130 (2003).
- 44 Antoniazzi F, Zamboni G, Lauriola S, Donadi L, Adami S, Tato L: Early bisphosphonate treatment in infants with severe osteogenesis imperfecta. *J. Pediatr.* 149(2), 174–179 (2006).
- 45 Landsmeer-Beker EA, Massa GG, Maaswinkel-Mooy PD, van de Kamp JJ, Papapoulos SE: Treatment of osteogenesis imperfecta with the bisphosphonate olpadronate (dimethylaminohydroxypropylidene bisphosphonate). *Eur. J. Pediatr.* 156(10), 792–794 (1997).
- 46 Sakkars R, Kok D, Engelbert R *et al.*: Skeletal effects and functional outcome with olpadronate in children with osteogenesis imperfecta: a 2-year randomised placebo-controlled study. *Lancet* 363(9419), 1427–1431 (2004).
- 47 Cho TJ, Choi IH, Chung CY, Yoo WJ, Park MS, Park YK: Efficacy of oral alendronate in children with osteogenesis imperfecta. *J. Pediatr. Orthop.* 25(5), 607–612 (2005).
- 48 DiMeglio LA, Peacock M: Two-year clinical trial of oral alendronate versus intravenous pamidronate in children with osteogenesis imperfecta. *J. Bone Miner. Res.* 21(1), 132–140 (2006).

- 49 Maasalu K, Haviko T, Martson A: Treatment of children with Osteogenesis imperfecta in Estonia. *Acta Paediatr.* 92(4), 452–455 (2003).
- 50 Madenci E, Yilmaz K, Yilmaz M, Coskun Y: Alendronate treatment in osteogenesis imperfecta. *J. Clin. Rheumatol.* 12(2), 53–56 (2006).
- 51 Seikaly MG, Kopanati S, Salhab N *et al.*: Impact of alendronate on quality of life in children with osteogenesis imperfecta. *J. Pediatr. Orthop.* 25(6), 786–791 (2009).
- 52 Ward LM, Glorieux FH, Rauch F, Verbruggen N, Heyden N, Lombardi A: A randomized, placebo-controlled trial of oral alendronate in children and adolescents with osteogenesis imperfecta. *Bone* 36(Suppl. 1), Oral Presentation 18 (2005).
- **Largest study assessing an oral agent (alendronate) in children with osteoporosis due to OI.**
- 53 Letocha AD, Cintas HL, Troendle JF *et al.*: Controlled trial of pamidronate in children with types III and IV osteogenesis imperfecta confirms vertebral gains but not short-term functional improvement. *J. Bone Miner. Res.* 20(6), 977–986 (2005).
- 54 Kok DH, Sakkars RJ, Janse AJ *et al.*: Quality of life in children with osteogenesis imperfecta treated with oral bisphosphonates (Olpadronate): a 2-year randomized placebo-controlled trial. *Eur. J. Pediatr.* 166(11), 1155–1161 (2007).
- 55 Ward LM, Shenouda N, Alos N *et al.*: Bone morbidity at diagnosis among children with acute lymphoblastic leukemia. *J. Bone Miner. Res.* 22(1), S489 (2007).
- 56 Thearle M, Horlick M, Bilezikian JP *et al.*: Osteoporosis: an unusual presentation of childhood Crohn's disease. *J. Clin. Endocrinol. Metab.* 85(6), 2122–2126 (2000).
- 57 Hogler W, Wehl G, van Staa T, Meister B, Klein-Franke A, Kropshofer G: Incidence of skeletal complications during treatment of childhood acute lymphoblastic leukemia: comparison of fracture risk with the General Practice Research Database. *Pediatr. Blood Cancer* 48(1), 21–27 (2007).
- 58 Baim S, Leonard MB, Bianchi ML *et al.*: Official positions of the International Society for Clinical Densitometry and executive summary of the 2007 ISCD Pediatric Position Development Conference. *J. Clin. Densitom.* 11(1), 6–21 (2008).
- **Position statement on the use and interpretation of bone mineral density by dual-energy x-ray absorptiometry in children.**
- 59 Halton J, Gaboury I, Grant R *et al.*: Advanced vertebral fracture among newly diagnosed children with acute lymphoblastic leukemia: results of the Canadian Steroid-Associated Osteoporosis in the Pediatric Population (STOPP) research program. *J. Bone Miner. Res.* 24(7), 1326–1334 (2009).
- 60 Nakhla M, Scuccimarrì R, Duffy KN *et al.*: Prevalence of Vertebral Fractures in Children with Chronic Rheumatic Diseases at Risk for Osteopenia. *J. Pediatr.* 154, 438–443 (2009).
- 61 Ward L, Tricco AC, Phuong P *et al.*: Bisphosphonate therapy for children and adolescents with secondary osteoporosis. *Cochrane Database Syst. Rev.* (4), CD005324 (2007).
- **Systematic review of the use of bisphosphonates in children with chronic illness.**
- 62 El-Husseini AA, El-Agroudy AE, El-Sayed MF, Sobh MA, Ghoneim MA: Treatment of osteopenia and osteoporosis in renal transplant children and adolescents. *Pediatr. Transplant.* 8(4), 357–361 (2004).
- 63 Rudge S, Hailwood S, Horne A, Lucas J, Wu F, Cundy T: Effects of once-weekly oral alendronate on bone in children on glucocorticoid treatment. *Rheumatology (Oxford)* 44(6), 813–818 (2005).
- 64 Golden NH, Iglesias EA, Jacobson MS *et al.*: Alendronate for the treatment of osteopenia in anorexia nervosa: a randomized, double-blind, placebo-controlled trial. *J. Clin. Endocrinol. Metab.* 90(6), 3179–3185 (2005).
- 65 Klein GL, Wimalawansa SJ, Kulkarni G, Sherrard DJ, Sanford AP, Herndon DN: The efficacy of acute administration of pamidronate on the conservation of bone mass following severe burn injury in children: a double-blind, randomized, controlled study. *Osteoporos. Int.* 16(6), 631–635 (2005).
- 66 Kim SD, Cho BS: Pamidronate therapy for preventing steroid-induced osteoporosis in children with nephropathy. *Nephron Clin. Pract.* 102(3–4), C81–C87 (2006).
- 67 Przkora R, Herndon DN, Sherrard DJ, Chinkes DL, Klein GL: Pamidronate preserves bone mass for at least 2 years following acute administration for pediatric burn injury. *Bone* 41(2), 297–302 (2007).
- 68 Acott PD, Wong JA, Lang BA, Crocker JF: Pamidronate treatment of pediatric fracture patients on chronic steroid therapy. *Pediatr. Nephrol.* 20(3), 368–373 (2005).
- 69 Lepore L, Pennesi M, Barbi E, Pozzi R: Treatment and prevention of osteoporosis in juvenile chronic arthritis with disodium clodronate. *Clin. Exp. Rheumatol.* 9(Suppl. 6), 33–35 (1991).
- 70 Carpenter PA, Hoffmeister P, Chesnut CH 3rd *et al.*: Bisphosphonate therapy for reduced bone mineral density in children with chronic graft-versus-host disease. *Biol. Blood Marrow Transplant.* 13(6), 683–690 (2007).
- 71 Plotkin H, Sueiro R: Osteoporosis in children with neuromuscular diseases and inborn errors of metabolism. *Minerva Pediatr.* 59(2), 129–135 (2007).
- 72 Henderson RC, Lark RK, Kecskemethy HH, Miller F, Harcke HT, Bachrach SJ: Bisphosphonates to treat osteopenia in children with quadriplegic cerebral palsy: a randomized, placebo-controlled clinical trial. *J. Pediatr.* 141(5), 644–651 (2002).
- 73 Plotkin H, Coughlin S, Kreikemeier R, Heldt K, Bruzoni M, Lerner G: Low doses of pamidronate to treat osteopenia in children with severe cerebral palsy: a pilot study. *Dev. Med. Child Neurol.* 48(9), 709–712 (2006).
- 74 Allington N, Vivegnis D, Gerard P: Cyclic administration of pamidronate to treat osteoporosis in children with cerebral palsy or a neuromuscular disorder: a clinical study. *Acta Orthop. Belg.* 71(1), 91–97 (2005).
- 75 Grissom LE, Kecskemethy HH, Bachrach SJ, McKay C, Harcke HT: Bone densitometry in pediatric patients treated with pamidronate. *Pediatr. Radiol.* 35(5), 511–517 (2005).
- 76 Bachrach SJ, Kecskemethy HH, Harcke HT, Lark RK, Miller F, Henderson RC: Pamidronate treatment and posttreatment bone density in children with spastic quadriplegic cerebral palsy. *J. Clin. Densitom.* 9(2), 167–174 (2006).
- 77 Apkon S, Coll J: Use of weekly alendronate to treat osteoporosis in boys with muscular dystrophy. *Am. J. Phys. Med. Rehabil.* 87(2), 139–143 (2008).
- 78 Hawker GA, Ridout R, Harris VA, Chase CC, Fielding LJ, Biggar WD: Alendronate in the treatment of low bone mass in steroid-treated boys with Duchennes muscular dystrophy. *Arch. Phys. Med. Rehabil.* 86(2), 284–288 (2005).
- 79 Krassas GE: Idiopathic juvenile osteoporosis. *Ann. NY Acad. Sci.* 900, 409–412 (2000).
- 80 Rauch F, Travers R, Norman ME, Taylor A, Parfitt AM, Glorieux FH: Deficient bone formation in idiopathic juvenile osteoporosis: a histomorphometric study of cancellous iliac bone. *J. Bone Miner. Res.* 15(5), 957–963 (2000).
- 81 Rauch F, Travers R, Norman ME, Taylor A, Parfitt AM, Glorieux FH: The bone formation defect in idiopathic juvenile osteoporosis is surface-specific. *Bone* 31(1), 85–89 (2002).

- 82 Gandrud LM, Cheung JC, Daniels MW, Bachrach LK: Low-dose intravenous pamidronate reduces fractures in childhood osteoporosis. *J. Pediatr. Endocrinol. Metab.* 16(6), 887–892 (2003).
- 83 Brumsen C, Hamdy NA, Papapoulos SE: Long-term effects of bisphosphonates on the growing skeleton. Studies of young patients with severe osteoporosis. *Medicine (Baltimore)* 76(4), 266–283 (1997).
- 84 Melchior R, Zabel B, Spranger J, Schumacher R: Effective parenteral clodronate treatment of a child with severe juvenile idiopathic osteoporosis. *Eur. J. Pediatr.* 164(1), 22–27 (2005).
- 85 Rauch F, Plotkin H, Travers R, Zeitlin L, Glorieux FH: Osteogenesis imperfecta types I, III, and IV: effect of pamidronate therapy on bone and mineral metabolism. *J. Clin. Endocrinol. Metab.* 88(3), 986–992 (2003).
- 86 Munns CF, Rajab MH, Hong J *et al.*: Acute phase response and mineral status following low dose intravenous zoledronic acid in children. *Bone* 41(3), 366–370 (2007).
- 87 Astrom E, Soderhall S: Beneficial effect of long term intravenous bisphosphonate treatment of osteogenesis imperfecta. *Arch. Dis. Child.* 86(5), 356–364 (2002).
- 88 Steelman J, Zeitler P: Treatment of symptomatic pediatric osteoporosis with cyclic single-day intravenous pamidronate infusions. *J. Pediatr.* 142(4), 417–423 (2003).
- 89 Ward LM, Denker AE, Porras A *et al.*: Single-dose pharmacokinetics and tolerability of alendronate 35- and 70-milligram tablets in children and adolescents with osteogenesis imperfecta type I. *J. Clin. Endocrinol. Metab.* 90(7), 4051–4056 (2005).
- 90 Zacharin M, Bateman J: Pamidronate treatment of osteogenesis imperfecta – lack of correlation between clinical severity, age at onset of treatment, predicted collagen mutation and treatment response. *J. Pediatr. Endocrinol. Metab.* 15(2), 163–174 (2002).
- 91 Dicuozzo G, Vincenzi B, Santini D *et al.*: Fever after zoledronic acid administration is due to increase in TNF- α and IL-6. *J. Interferon Cytokine Res.* 23(11), 649–654 (2003).
- 92 Pecherstorfer M, Jilch R, Sauty A *et al.*: Effect of first treatment with aminobisphosphonates pamidronate and ibandronate on circulating lymphocyte subpopulations. *J. Bone Miner. Res.* 15(1), 147–154 (2000).
- 93 Janssen van Doorn K, Neyns B, Van der Niepen P, Verbeelen D: Pamidronate-related nephrotoxicity (tubulointerstitial nephritis) in a patient with osteolytic bone metastases. *Nephron* 89(4), 467–468 (2001).
- 94 Machado CE, Flombaum CD: Safety of pamidronate in patients with renal failure and hypercalcemia. *Clin. Nephrol.* 45(3), 175–179 (1996).
- 95 de Groen PC, Lubbe DF, Hirsch LJ *et al.*: Esophagitis associated with the use of alendronate. *N. Engl. J. Med.* 335(14), 1016–1021 (1996).
- 96 Malik AR, Campbell SH, Toma NM: Bilateral acute anterior uveitis after alendronate. *Br. J. Ophthalmol.* 86(12), 1443 (2002).
- 97 Rey J, Daumen-Legre V, Pham T *et al.*: Uveitis, an under-recognized adverse effect of pamidronate. Case report and literature review. *Joint Bone Spine* 67(4), 337–340 (2000).
- 98 Richards JC, Wiffen SJ: Corneal graft rejection precipitated by uveitis secondary to alendronate sodium therapy. *Cornea* 25(9), 1100–1101 (2006).
- 99 Heckbert SR, Li G, Cummings SR, Smith NL, Psaty BM: Use of alendronate and risk of incident atrial fibrillation in women. *Arch. Intern. Med.* 168(8), 826–831 (2008).
- 100 Grosso A, Douglas I, Hingorani A, MacAllister R, Smeeth L: Oral bisphosphonates and risk of atrial fibrillation and flutter in women: a self-controlled case-series safety analysis. *PLoS ONE* 4(3), E4720 (2009).
- 101 Gluck O, Maricic M: Infusion therapies in rheumatic practice. *J. Clin. Rheumatol.* 6(5), 294–299 (2000).
- 102 Lin JH: Bisphosphonates: a review of their pharmacokinetic properties. *Bone* 18(2), 75–85 (1996).
- 103 Kasting GB, Francis MD: Retention of etidronate in human, dog, and rat. *J. Bone Miner. Res.* 7(5), 513–522 (1992).
- 104 Papapoulos SE, Cremers SC: Prolonged bisphosphonate release after treatment in children. *N. Engl. J. Med.* 356(10), 1075–1076 (2007).
- 105 Djokanovic N, Klieger-Grossmann C, Koren G: Does treatment with bisphosphonates endanger the human pregnancy? *J. Obstet. Gynaecol. Can.* 30(12), 1146–1148 (2008).
- **Review of clinical outcomes following *in utero* exposure to bisphosphonates.**
- 106 Levy S, Favez I, Taguchi N *et al.*: Pregnancy outcome following *in utero* exposure to bisphosphonates. *Bone* 44(3), 428–430 (2009).
- 107 Munns CF, Rauch F, Ward L, Glorieux FH: Maternal and fetal outcome after long-term pamidronate treatment before conception: a report of two cases. *J. Bone Miner. Res.* 19(10), 1742–1745 (2004).
- 108 Andreadis C, Charalampidou M, Diamantopoulos N, Chouchos N, Mouratidou D: Combined chemotherapy and radiotherapy during conception and first two trimesters of gestation in a woman with metastatic breast cancer. *Gynecol. Oncol.* 95(1), 252–255 (2004).
- 109 Al Muderis M, Azzopardi T, Cundy P: Zebra lines of pamidronate therapy in children. *J. Bone Joint Surg. Am.* 89(7), 1511–1516 (2007).
- 110 Grissom LE, Harcke HT: Radiographic features of bisphosphonate therapy in pediatric patients. *Pediatr. Radiol.* 33(4), 226–229 (2003).
- 111 Rauch F, Travers R, Munns C, Glorieux FH: Sclerotic metaphyseal lines in a child treated with pamidronate: histomorphometric analysis. *J. Bone Miner. Res.* 19(7), 1191–1193 (2004).
- 112 Smith EJ, Little DG, Briody JN *et al.*: Transient disturbance in physal morphology is associated with long-term effects of nitrogen-containing bisphosphonates in growing rabbits. *J. Bone Miner. Res.* 20(10), 1731–1741 (2005).
- 113 Whyte MP, Wenkert D, Clements KL, McAlister WH, Mumm S: Bisphosphonate-induced osteopetrosis. *N. Engl. J. Med.* 349(5), 457–463 (2003).
- 114 Whyte MP, McAlister WH, Novack DV, Clements KL, Schoenecker PL, Wenkert D: Bisphosphonate-induced osteopetrosis: novel bone modeling defects, metaphyseal osteopenia, and osteosclerosis fractures after drug exposure ceases. *J. Bone Miner. Res.* 23(10), 1698–1707 (2008).
- **Adverse effects of pamidronate overdose.**
- 115 Misof BM, Roschger P, Baldini T *et al.*: Differential effects of alendronate treatment on bone from growing osteogenesis imperfecta and wild-type mouse. *Bone* 36(1), 150–158 (2005).
- 116 Bikle DD, Morey-Holton ER, Doty SB, Currier PA, Tanner SJ, Halloran BP: Alendronate increases skeletal mass of growing rats during unloading by inhibiting resorption of calcified cartilage. *J. Bone Miner. Res.* 9(11), 1777–1787 (1994).
- 117 Ward KA, Adams JE, Freemont TJ, Mughal MZ: Can bisphosphonate treatment be stopped in a growing child with skeletal fragility? *Osteoporos. Int.* 18(8), 1137–1140 (2007).
- 118 Munns CF, Rauch F, Zeitlin L, Fassier F, Glorieux FH: Delayed osteotomy but not fracture healing in pediatric osteogenesis imperfecta patients receiving pamidronate. *J. Bone Miner. Res.* 19(11), 1779–1786 (2004).
- 119 Pizones J, Plotkin H, Parra-Garcia JI *et al.*: Bone healing in children with osteogenesis imperfecta treated with bisphosphonates. *J. Pediatr. Orthop.* 25(3), 332–335 (2005).

- 120 Marini JC: Do bisphosphonates make children's bones better or brittle? *N. Engl. J. Med.* 349(5), 423–426 (2003).
- 121 Camacho NP, Raggio CL, Doty SB *et al.*: A controlled study of the effects of alendronate in a growing mouse model of osteogenesis imperfecta. *Calcif. Tissue Int.* 69(2), 94–101 (2001).
- 122 Evans KD, Lau ST, Oberbauer AM, Martin RB: Alendronate affects long bone length and growth plate morphology in the oim mouse model for Osteogenesis Imperfecta. *Bone* 32(3), 268–274 (2003).
- 123 Zeitlin L, Rauch F, Plotkin H, Glorieux FH: Height and weight development during four years of therapy with cyclical intravenous pamidronate in children and adolescents with osteogenesis imperfecta types I, III, and IV. *Pediatrics* 111(5 Part 1), 1030–1036 (2003).
- 124 Wysowski DK: Reports of esophageal cancer with oral bisphosphonate use. *N. Engl. J. Med.* 360(1), 89–90 (2009).
- 125 Bamias A, Kastiris E, Bamia C *et al.*: Osteonecrosis of the jaw in cancer after treatment with bisphosphonates: incidence and risk factors. *J. Clin. Oncol.* 23(34), 8580–8587 (2005).
- 126 Murad OM, Arora S, Farag AF, Guber HA: Bisphosphonates and osteonecrosis of the jaw: a retrospective study. *Endocr. Pract.* 13(3), 232–238 (2007).
- 127 Pazianas M, Miller P, Blumentals WA, Bernal M, Kothawala P: A review of the literature on osteonecrosis of the jaw in patients with osteoporosis treated with oral bisphosphonates: prevalence, risk factors, and clinical characteristics. *Clin. Ther.* 29(8), 1548–1558 (2007).
- 128 Malmgren B, Astrom E, Soderhall S: No osteonecrosis in jaws of young patients with osteogenesis imperfecta treated with bisphosphonates. *J. Oral Pathol. Med.* 37(4), 196–200 (2008).
- 129 Burnham JM, Shults J, Dubner SE, Sembhi H, Zemel BS, Leonard MB: Bone density, structure, and strength in juvenile idiopathic arthritis: importance of disease severity and muscle deficits. *Arthritis Rheum.* 58(8), 2518–2527 (2008).
- 130 Leonard MB: A structural approach to skeletal fragility in chronic kidney disease. *Semin. Nephrol.* 29(2), 133–143 (2009).
- 131 Dubner SE, Shults J, Baldassano RN *et al.*: Longitudinal assessment of bone density and structure in an incident cohort of children with Crohn's disease. *Gastroenterology* 136(1), 123–130 (2009).

Reproduced with permission of the copyright owner. Further reproduction prohibited without permission.